



**Cuyahoga County
Medical Examiner's Office**
11001 Cedar Avenue, Cleveland, Ohio 44106
MEDICAL EXAMINER'S VERDICT

Thomas P. Gilson, M.D.
Medical Examiner

**THE STATE OF OHIO,
SS.
CUYAHOGA COUNTY**

CASE NUMBER: IN2014-01991

Be it Remembered, That on the **23rd** day of **November, 2014** information was given to me, **Thomas P. Gilson, M.D.**, Medical Examiner of said County, that the dead body of **a boy** supposed to have come to **his** death as the result of criminal or other violent means, or by casualty, or by suicide, or suddenly when in apparent health, or in any suspicious or unusual manner, (Sec. 313-11, 313-12 R.C. Ohio) had been found **in MetroHealth Medical Center in Cleveland** of Cuyahoga County, on the **23rd** day of **November, 2014**.


I viewed or caused to be viewed the said body at the Medical Examiner's Office. After the viewing and making inquiry into the circumstances that caused the death of the said person, I obtained further information, to-wit: **(CPD #2014-00370224) (MHMC #5270248)**. I also carefully examined or caused to be examined the said dead body at **8:30AM** on the **24th** day of **November, 2014** and I find as follows: to wit:

I, **Thomas P. Gilson, M.D.**, Medical Examiner of said county, having diligently inquired, do true presentment make in what manner **Tamir E. Rice**, whose body was at the Medical Examiner's Office on the **24th** day of **November, 2014** came to **his** death. The said **Tamir E. Rice** was **single, 12 years** of age, a resident of **Cleveland, Cuyahoga County, Ohio**, and a native of **Cleveland, Ohio**; was of the **Black** race, and had **brown** eyes, **black** hair, **no** beard, **no** mustache, was **67 inches** in height, and weighed **195 pounds**.

Upon full inquiry based on all the known facts, I find that the said **Tamir E. Rice** came to **his** death officially on the **23rd** day of **November, 2014** in MetroHealth Medical Center and was officially pronounced dead at 12:54 A.M., by Dr. Patel. There is history that on November 22nd, 2014 at about 3:30 P.M., the said Tamir E. Rice, 2006 West 100th Street, was outside of Cudell Recreation Center at 1910 West Boulevard, when he was shot by a police officer during legal intervention, and then collapsed to the ground. The Cleveland Paramedics were called and on arrival, treatment was administered. This boy was then transported to MetroHealth Medical Center where he was admitted with the aforementioned injuries. Treatment and drug therapy were administered and an operative procedure was performed. Supportive care was maintained, however, the said Tamir E. Rice failed to respond and was pronounced dead at the aforementioned time and date. The County Medical Examiner's Office was notified and Esposito Mortuary Services was dispatched. This boy was then transported to the Medical Examiner's Office where an autopsy was performed. That death in this case was the end result of gunshot wound of torso with injuries of major vessel, intestines and pelvis, and was homicidal in nature.


Cause of Death: Gunshot wound of torso with injuries of major vessel, intestines and pelvis.
HOMICIDE.

Tamir E. Rice
(Name of Deceased)


_____, M.D.
Cuyahoga County Medical Examiner



Toxicology Laboratory Report
Cuyahoga County Regional Forensic Science Laboratory
 11001 Cedar Avenue, Cleveland, Ohio 44106
Final Report



Case Number : IN2014-01991	Report Date : Thursday, December 11, 2014
Name : Tamir Rice	Receipt Date : Monday, November 24, 2014
Agency : Cuyahoga County (CCMEO)	Pathologist : TGIL - Thomas Gilson - M.D.

Specimen Received

B1 - Blood	F1 - Femoral Blood	G1 - Gastric	I1 - Bile
L1 - Liver	R1 - Longterm Storage	R2 - Longterm Storage	V1 - Vitreous Humor
Y1 - Hospital Blood	Y2 - Hospital Blood	Y3 - Hospital Blood	Y4 - Hospital Blood

COMMENT : Y1 = 11/22/14 @ 526pm; Y2 and Y3 = 11/22/14 @ 751pm; Y4 = 11/22/14 @ 951pm

B1: Heart Blood Analysis			
Drug Group/Class	Result	Quantitation	Analyte(s)
Acid Neutrals by GC/MS	None Detected		See Page 4, Group 2
Acetaminophen Screen	None Detected		See Page 4, Group 9
Salicylate Screen	None Detected		See Page 4, Group 10

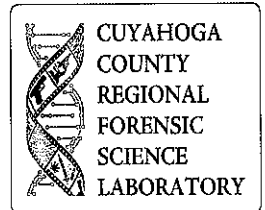
F1: Femoral Blood Analysis			
Drug Group/Class	Result	Quantitation	Analyte(s)
Volatile Screen & Confirmation	None Detected		See Page 4, Group 1
Opiate ELISA Screen	None Detected		See Page 4, Group 7
Basic Drugs by GC/MS	None Detected		See Page 4, Group 8
Amphetamine ELISA	None Detected		See Page 4, Group 7
Barbiturates ELISA Screen	None Detected		See Page 4, Group 7
Benzodiazepines ELISA Screen	None Detected		See Page 4, Group 7
Cannabinoids ELISA Screen	None Detected		See Page 4, Group 7
Carisoprodol ELISA Screen	None Detected		See Page 4, Group 7
Cocaine Mtb. ELISA Screen	None Detected		See Page 4, Group 7
Fentanyl ELISA Screen	None Detected		See Page 4, Group 7
Methamphetamine ELISA Screen	None Detected		See Page 4, Group 7
Oxycodone ELISA Screen	None Detected		See Page 4, Group 7
Phencyclidine ELISA Screen	None Detected		See Page 4, Group 7
Tricyclic Antidepressants ELISA Screen	None Detected		See Page 4, Group 7
Methadone ELISA Screen	None Detected		See Page 4, Group 7

G1: Gastric Contents Analysis			
Drug Group/Class	Result	Quantitation	Analyte(s)
No Test Performed	---		

I 1: Bile Analysis			
Drug Group/Class	Result	Quantitation	Analyte(s)
No Test Performed	---		



Toxicology Laboratory Report
Cuyahoga County Regional Forensic Science Laboratory
 11001 Cedar Avenue, Cleveland, Ohio 44106
Final Report



Case Number : IN2014-01991	Report Date : Thursday, December 11, 2014
Name : Tamir Rice	Receipt Date : Monday, November 24, 2014
Agency : Cuyahoga County (CCMEO)	Pathologist : TGIL - Thomas Gilson - M.D.

L 1: Liver Analysis			
Drug Group/Class	Result	Quantitation	Analyte(s)
No Test Performed	---		

R 1: Long Term Storage Blood Analysis			
Drug Group/Class	Result	Quantitation	Analyte(s)
No Test Performed	---		

R 2: Long Term Storage Purple Top			
Drug Group/Class	Result	Quantitation	Analyte(s)
No Test Performed	---		


V 1: Vitreous Humor Post Analysis			
Drug Group/Class	Result	Quantitation	Analyte(s)
No Test Performed	---		

Y 1: Hospital Blood Light-Blue Top Analysis			
Drug Group/Class	Result	Quantitation	Analyte(s)
Volatile Screen & Confirmation	None Detected		See Page 4, Group 1
Acid Neutrals by GC/MS	Qty. Insufficient		See Page 4, Group 2
Opiate ELISA Screen	None Detected		See Page 4, Group 7
Basic Drugs by GC/MS	Positive		See Page 4, Group 8
Lidocaine		Positive	
Acetaminophen Screen	Qty. Insufficient		See Page 4, Group 9
Salicylate Screen	Qty. Insufficient		See Page 4, Group 10
Amphetamine ELISA	None Detected		See Page 4, Group 7
Barbiturates ELISA Screen	None Detected		See Page 4, Group 7
Benzodiazepines ELISA Screen	None Detected		See Page 4, Group 7
Cannabinoids ELISA Screen	None Detected		See Page 4, Group 7
Carisoprodol ELISA Screen	None Detected		See Page 4, Group 7
Cocaine Mtb. ELISA Screen	None Detected		See Page 4, Group 7
Fentanyl ELISA Screen	None Detected		See Page 4, Group 7
Methamphetamine ELISA Screen	None Detected		See Page 4, Group 7
Oxycodone ELISA Screen	None Detected		See Page 4, Group 7
Phencyclidine ELISA Screen	None Detected		See Page 4, Group 7
Tricyclic Antidepressants ELISA Screen	None Detected		See Page 4, Group 7

Handwritten initials/signature



Toxicology Laboratory Report
Cuyahoga County Regional Forensic Science Laboratory
11001 Cedar Avenue, Cleveland, Ohio 44106
Final Report



Case Number : IN2014-01991 **Report Date :** Thursday, December 11, 2014
Name : Tamir Rice **Receipt Date :** Monday, November 24, 2014
Agency : Cuyahoga County (CCMEO) **Pathologist :** TGIL - Thomas Gilson - M.D.

Y 1: Hospital Blood Light-Blue Top Analysis			
Drug Group/Class	Result	Quantitation	Analyte(s)
Methadone ELISA Screen	None Detected		See Page 4, Group 7

Y 2: Serum from Hospital Blood			
Drug Group/Class	Result	Quantitation	Analyte(s)
No Test Performed	---		

Y 3: Hospital Blood Pink Top Analysis			
Drug Group/Class	Result	Quantitation	Analyte(s)
No Test Performed	---		

Y 4: Hospital Blood Analysis			
Drug Group/Class	Result	Quantitation	Analyte(s)
No Test Performed	---		

Handwritten initials

Toxicology Laboratory Report
Cuyahoga County Regional Forensic Science Laboratory
11001 Cedar Avenue, Cleveland, Ohio 44106
Final Report

Page 4 of 4

Analytes included in Drug Groups / Class

DRUGS ANALYZED/QUANTIFIED BY CCRFSL/CCMEO TOXICOLOGY

- 1) **VOLATILES:** Acetaldehyde, Acetone, Acetonitrile*, Butane, Chloroform*, Dichloromethane*, Ethanol, Ethyl Acetate*, Formaldehyde, Isopropanol, Methane, Methanol, Paraldehyde*, Propane, Toluene*. **ETHANOL, ACETONE, ISOPROPANOL, and METHANOL CONFIRMATION(s)** by alternative GC column and/or alternative specimens. **METHANOL** is differentiated from **FORMALDEHYDE** by Colorimetry (Qualitative).
- 2) **Sedatives, Hypnotics, Anti-Epileptic and Other Acidic/Neutral Drugs:** Amobarbital, Butalbital, Caffeine, Carbamazepine, Carisoprodol, Glutethimide, Ibuprofen, Levetiracetam, Mephenytoin, Meprobamate, Metaxalone, Naproxen, Pentobarbital, Pentoxifylline, Phenobarbital, Phenytoin, Primidone, Secobarbital, Theophylline, Topiramate, (Gabapentin/Pregabalin by LC/MS/MS); **ACIDIC NEUTRALS Screened and Quantified by GC-FID and Confirmed by GC/MS.**
- 3) **CARBON MONOXIDE*(Carboxyhemoglobin)** by CO-Oximetry: Carbon Monoxide, Methemoglobin, Hemoglobin; **CARBON MONOXIDE CONFIRMATION** by Spectrophotometry and/or Microdiffusion.
- 4) **GLYCOLS*:** Ethylene Glycol, Propylene Glycol Screened and Confirmed by GC/MS.
- 5) **CYANIDE*:** Screened and Quantified by Colorimetry.
- 6) **EMIT@SCREEN: SYMPATHOMIMETIC AMINES (SMAs)** (target = d-Amphetamine); **BENZODIAZEPINES** (Target= Oxazepam); **COCAINE** (Target= Benzoyllecgonine (a cocaine metabolite); **CANNABINOIDS** (Target= 11-nor- Δ -9-THC-COOH (a marijuana metabolite); **OPIATES** (Target= Morphine); **PHENCYCLIDINE** (Target= Phencyclidine).
- 7) **ELISA (Enzyme-Linked Immunosorbent Assay) SCREEN: SMAs** (Target = d-Amphetamine); **Barbiturates** (Target = Pentobarbital); **Benzodiazepines** (Target = Alprazolam); **Cannabinoids** (Target = 11-nor- Δ -9-THC-COOH (a marijuana metabolite); **Carisoprodol** (Target = Carisoprodol); **Cocaine Metabolite** (Target = Benzoyllecgonine); **Fentanyl** (Target = Fentanyl); **Methamphetamine** (Target = d-Methamphetamine); **Oxycodone** (Target = Oxycodone); **Phencyclidine** (Target = Phencyclidine); **Tricyclic Antidepressants** (Target = Nortriptyline); **Methadone** (Target = Methadone); **Opiates** (Target = Morphine).
- 8) **BASIC DRUGS by GC/MS (Quantitation and Confirmation):** Amantadine, Amitriptyline, Amoxapine, Amphetamine, Atropine, Benzotropine, Brompheniramine, Bupivacaine, Bupropion, Bupropion Metabolites, Buspirone, Caffeine, Carbinoxamine, Chlorophenylpiperazine, Chlorpheniramine, Chlorpromazine, Citalopram, Clomipramine, Clozapine, Cocaethylene, Cocaine, Codeine, Cocaine and metabolites, Cotinine, Cyclizine, Cyclobenzaprine, Desalkylflurazepam, Desipramine, Desmethyl Chloridiazepoxide, Desmethyl Clomipramine, Desmethyl Clozapine, Desmethylsertraline, Desmethylvenlafaxine, Dextromethorphan, Diazepam, Diethylpropion, Diphenhydramine, Disopyramide, Diltiazem, Doxepin, Doxylamine, Ecgonine methyl ester, Ephedrine/Pseudoephedrine, Fenfluramine, Fentanyl, Fluoxetine, Fluvoxamine, Guaifenesin, Haloperidol, Hydrocodone, Hydroxyzine, Imipramine, Ketamine, Laudanosine, Lidocaine, Lidocaine mb (MEGX), Loxapine, Maprotiline, Meclizine, Meperidine, Mephentermine, Mesoridazine, Methadone, Methadone primary mb (EDDP), Methadone secondary mb (EMDP), Methamphetamine, Methylene-dioxyamphetamine (MDA), Methylene-dioxyamphetamine (MDMA), Methylene-dioxypropylvalerone (MDPV), Methylphenidate, Metoprolol, Mexiletine, Midazolam, Mirtazapine, Nefazodone, Nicotine, Nordiazepam, Nordoxepin, Norfluoxetine, Normeperidine, Norpropoxyphene, Nortriptyline, Norverapamil, Olanzapine, Orphenadrine, Oxycodone, Papaverine, Paroxetine, Pentazocine, Pentoxifylline, Perphenazine, Phencyclidine, beta-Phenethylamine, Pheniramine, Phendimetrazine, Phenmetrazine, Phentermine, Phenylpropranolamine, Phenyltoloxamine, Procaine, Promethazine, Propoxyphene, Propranolol, Protriptyline, Pseudoephedrine, Pyrilamine, Quetiapine, Quinidine, Quinine, Sertraline, Thioridazine, Tramadol, Tranylcypromine, Trazodone, Trihexylphenidyl, Trimipramine, Venlafaxine, Verapamil, Zolpidem.
- 9) **ACETAMINOPHEN SCREEN:** Acetaminophen by Colorimetry (Qualitative).
- 10) **SALICYLATE SCREEN:** Salicylate (Aspirin) by Colorimetry (Qualitative), **SALICYLATE CONFIRMATION** by Gas Chromatography.
- 11) **XANTHINES** by GC/MS: Acetaminophen, Caffeine.
- 12) **CLINICAL CHEMISTRIES (CHEM7):** Ketones, pH, Specific Gravity, and Electrolytes (Sodium, Potassium, Chloride, TCO₂, Glucose, Urea, Creatinine).
- 13) **COCAINE CONFIRMATION** by GC/MS: Anhydroecgonine methyl ester, Benzoyllecgonine, Cocaine, Cocaethylene, Ecgonine ethyl ester*, Ecgonine methyl ester.
- 14) **CANNABINOIDS** by GC/MS: Cannabinoids (ng/mL; mcg/L): D⁹-THC, 11-OH-D⁹-THC (a marijuana metabolite), 11-nor-D⁹-THC-COOH (a marijuana metabolite), TOTAL 11-nor-D⁹-THC-COOH (a marijuana metabolite).
- 15) **OPIATES** by GC/MS (ng/mL): Morphine, 6-Acetylmorphine (heroin metabolite), Codeine, Hydrocodone, Dihydrocodeine, Hydromorphone, Norcodeine*, Oxycodone, Oxymorphone. **TOTAL OPIATES** by GC/MS-Hydrolysis followed by **OPIATES** by GC/MS.
- 16) **BENZODIAZEPINE CONFIRMATION** by GC/MS: Alprazolam/ metabolite, Diazepam/ metabolites, Clonazepam, Lorazepam, Midazolam/metabolite, Triazolam.
- 17) **SYMPATHOMIMETIC AMINES CONFIRMATION** by GC/MS analysis (ng/mL): Amantadine, Amphetamine, beta-Phenethylamine, MDEA, Methamphetamine, Methylene-dioxyamphetamine (MDA), Methylene-dioxyamphetamine (MDMA), Phentermine, Phenylpropranolamine, Pseudoephedrine.
- 18) **GHB** by GC/MS (mg/L): Gamma-hydroxybutyric acid (gamma hydroxybutyrate).
- 19) **FENTANYL** by GC/MS (ng/mL): Fentanyl, Sufentanil, Alfentanil.
- 20) **SENT OUT TO REFERENCE LABS:** Synthetic Cannabinoids and Synthetic Cathinones, Epinephrine, 7-amino Flunitrazepam, Flunitrazepam, IgE, Insulin, LSD, Nefedipine, C-Peptide, Psilocin, Risperidone, Tryptase, Warfarin, Valproic Acid, **HEAVY METAL SCREEN:** (Antimony, Arsenic, Lead, Barium, Cadmium, Bismuth, Mercury, Selenium) or any other drugs not listed above.

*BY REQUEST ONLY; **ABBREVIATIONS:** POS=Positive; NEG=Negative; UNS=Specimen unsuitable for testing; NTDN=Not Done; QNS=Quantity insufficient for analysis; CHEM7=Clinical Chemistry; <=less than; >=greater than; LRL= Lower reporting limit; C.L. = Confidence Level.
UNITS FOR VOLATILES: 100 mg/dL = 0.100 g/dL = 0.100 g/100 mL. **UNITS:** 1 mg/L = 1000 µg/L = 1000 ng/mL.

I certify that the specimen identified by this case, number IN2014-01991 have been handled and analyzed in accordance with all applicable requirements. The result in this report relate to the items tested. For purposes of identification and case tracking the Toxicology Lab uses case numbers exclusively. Name is subject to change based on receipt of information. This report shall not be reproduced except in full, without the written approval of the Cuyahoga County Regional Forensic Science Laboratory.

Chief Forensic Toxicologist *Harold E. Schuster* 12/12/14



**Cuyahoga County
Medical Examiner's Office**
11001 Cedar Avenue, Cleveland, Ohio 44106
REPORT OF AUTOPSY

Thomas P. Gilson, M.D.
Medical Examiner

**THE STATE OF OHIO,
SS.
CUYAHOGA COUNTY**

CASE NUMBER: IN2014-01991

**REPORT OF AUTOPSY OF: Tamir E. Rice
ADDRESS: 2006 West 100th Street, Cleveland, Ohio**

I, **Thomas P. Gilson, M.D.**, Medical Examiner of Cuyahoga County, Ohio, Certify that on the **24th** day of **November, 2014** at **11:00 AM** in accordance with Section 313.13 of the Revised Code, of the State of Ohio, an autopsy was performed on the body of **Tamir E. Rice**.

The following is the report of autopsy to the best of my knowledge and belief: This person was a **male, single**, aged **12 years**, of the **Black** race; had **brown** eyes, **black** hair, **good** teeth, was **67 inches** in height, weighing **195 pounds**; a native of **Cleveland, Ohio**.

FINAL DIAGNOSES:

- I. Penetrating gunshot wound of torso with
 - A. Status post surgical intervention (perforations of inferior vena cava and intestines, anamnestic)
 - B. Fracture of pelvis
 - C. Bullet recovered

- II. Status post attempted resuscitation with edema


Cause of Death: Gunshot wound of torso with injuries of major vessel, intestines and pelvis.
HOMICIDE.

Thomas P. Gilson, M.D.

(Name of Pathologist)

Tamir E. Rice

(Name of Deceased)



Pathologist Signature

Cuyahoga County Medical Examiner

,M.D.

Case: IN2014-01991
Name: Tamir E. Rice

County: Cuyahoga

AUTOPSY REPORT

NAME: Tamir E. Rice

CASE#: IN2014-01991

I hereby certify that I, Thomas Gilson, M.D., Medical Examiner, have performed an autopsy on the body of Tamir E. Rice on the 24th day of November, 2014 commencing at 11:00 A.M. in the mortuary of the Cuyahoga County Medical Examiner's Office.

The body is identified by Medical Examiners tags attached to both great toes.

The body is received in a secured fashion from the hospital.

EXTERNAL EXAMINATION:

The body is of a well developed, well nourished, edematous, 67 inch, 195 pound, black adolescent male, whose appearance is consistent with the reported age of 12 years or older.

Wiry black scalp hair measures up to 1 ½". The irides are brown; the conjunctivae are edematous without hemorrhage, petechiae, or jaundice. Natural teeth are in the maxilla and mandible; the frenula are intact. The facial bones are intact to palpation. The ears and neck are unremarkable. The trachea is in the midline.

The anterior and posterior aspects of the torso are unremarkable except as noted below. The upper and lower extremities are without palpable fractures. The external genitalia are apparently circumcised male with testes in the scrotal sac. The anus is unremarkable except for scant fecal soiling.

The head, neck, extremities, external genitalia, anus and back are free of trauma.

Postmortem Changes: Rigor mortis is well developed in the jaw and extremities. Blanching livor mortis is at the back except for the pressure points. The body is cold.

Scars: On the left upper quadrant of the abdomen is a 1" scar. There is a ½" scar in the lower midline of the back. On the posterior aspect of the right forearm are two 1" scars. There is a ½" scar on the right calf. There are two 1" scars near the right ankle posteriorly. There are ½" scars near the anterior aspect of the ankles (right and left). There is multifocal irregular scarring of the knees.

Tattoos: None.

Clothing: None.

Therapeutic Procedures: A nasogastric tube enters the right nostril and is properly positioned. There are bilateral nasal packings. An endotracheal tube is present and properly positioned. An oral temperature probe is also present and properly positioned. The endotracheal tube is secured with a tie. There is a triple lumen catheter in the left infraclavicular area. Electrocardiogram leads are on the shoulders and left side of the abdomen. An intravenous catheter is in the right antecubital fossa and another at the left antecubital fossa. There are bilateral gauze wrist restraints. There are puncture sites at the anterolateral aspect of the wrists bilaterally. Ecchymoses are noted. There is a Foley catheter present with a transducer lead also noted. There are two puncture sites on the dorsal left foot. There are ink impressions on the feet (consistent with Doppler vascular monitoring). There are ace wraps on both distal lower extremities and the ankles have been tied together in characteristic postmortem practice. Further interventions are described in the "INJURIES" section.

Injuries, Internal and External: There is a penetrating gunshot wound of the torso. Directions are given on standard anatomical planes.

There is an entrance gunshot wound on the left side of the abdomen slightly above the umbilicus located 23 ½" below the top of the head and ½" to the left of midline. It is a ½" ovoid defect with a margin of abrasion measuring up to 1/16" to the left. There is no soot or stippling of the adjacent skin. There is a 1 ½" area of violet contusion lateral to the gunshot defect. The gunshot lies within suture closing a 12 ½" vertical incision which extends through the midline of the abdomen from the epigastrium

Case: IN2014-01991
Name: Tamir E. Rice

County: Cuyahoga

towards the pelvis. There is violet discoloration at the inferior abdomen near the bottom of the incision.

Path of the bullet:

After perforating the skin and subcutaneous soft tissue the bullet continues through the peritoneal cavity. At this point the wound track is altered by surgical intervention. There is a resection of a portion of jejunum and transverse colon. There are stapled resection margins at either side of the jejunum and transverse colon. The surgical margins are intact and free of disruption. There are multiple surgical vascular ligations including a closure of the inferior vena cava proximal to a gunshot injury below the level of the renal veins. The bullet perforated the right side of the pelvis near the spine. There is apparent bone wax in the pelvis defect. There is approximately 75 ml. of bloody fluid in the abdomen and two surgical sponges (saturated with bloody fluid) are recovered. The aorta and spine adjacent to the wound path are not injured.

The body is generally edematous consistent with fluid resuscitation.

The direction this bullet traveled is front to back, left to right and downward. The bullet lodged in the pelvis approximately 26" below the top of the head and 1" to the right of midline. The wound track is hemorrhagic.

The recovered bullet is metal jacketed and moderately deformed with mushrooming at the nose. It appears to be of medium caliber and is now inscribed "TR" on the base and submitted to evidence after being photographed.

Incisions of the wrists and ankles confirm the previous therapeutic interventions and reveal no evidence of additional injury.

Additional injuries:

In the right axilla is a 2" violet contusion at the anterior axillary line. There is a 1/4" x 1/4" abraded contusion in the lateral left upper quadrant of the abdomen and two 1/8" abraded contusions in the left lower quadrant of the abdomen.

These injuries, having been described, will not be repeated.

INTERNAL EXAMINATION:

Head: The scalp is free of contusion. The skull is free of fracture. There is no epidural, subdural, or subarachnoid hemorrhage. The 1570 gram symmetrical brain has a normal distribution of cranial nerves and the cerebral vessels are without lesion. The white and gray matter are remarkable for widening of the gyri with associated narrowing of the sulci. The ventricles are slightly compressed. The parenchyma is free of hemorrhage and mass lesions. The substantia nigra is normally pigmented. The pons, medulla, and cerebellum are not remarkable.

Neck: The cervical vertebrae, hyoid bone, tracheal and laryngeal cartilages, and the paratracheal soft tissues are without lesion except for hemorrhage near the intubation site at the upper airway. There is also a slight amount of edema noted here. The strap muscles of the neck are free of hemorrhage. The upper airway is not obstructed. The tongue is unremarkable.

Body Cavities: The organ situs is generally normal except as noted above. There are no adhesions. There is approximately 850 ml. of serosanguineous fluid in the right chest cavity and 550 ml. of similar fluid in the left chest cavity. Within the pericardial sac is approximately 75 ml. of serous fluid. There is hemorrhage near the previously described surgical sites. The abdomen contains approximately 75 ml. of bloody fluid with two surgical sponges as noted above.

Cardiovascular System: The aorta is free of atherosclerosis. The venae cavae and pulmonary arteries are without thrombus or embolus. The inferior vena cava shows the previously noted changes. The 360 gram heart has a normal distribution of right predominant coronary arteries. The epicardial coronary vessels are free of atherosclerosis and thrombi. The myocardium is uniformly reddish-brown without hemorrhage, softening, pallor, or fibrosis. The left ventricle is 1.3 cm. thick; the right ventricle is 0.3 cm. thick. The endocardial surfaces and cardiac valves are not remarkable.

Respiratory System: The right lung weighs 600 grams; the left lung weighs 490 grams. Both lungs are pink and crepitant with dark purple, dependent congestion. The parenchyma is free of consolidation and mass lesions. The vasculature is unremarkable. The bronchi are not obstructed. On section the cut surface exudes a moderate amount of tan frothy fluid.

Liver, Gallbladder, and Pancreas: The 1410 gram liver has a smooth intact capsule with homogeneous brown parenchyma that is free of fibrosis and mass lesions. The gallbladder contains approximately 7 ml. of dark green fluid bile without stones. The extrahepatic bile ducts are unremarkable. The pancreas is tan, lobulated and of usual consistency. It is free of hemorrhage, necrosis, and calcification.

Hemic and Lymphatic System: The 240 gram spleen has a dark purple, intact, smooth capsule and firm, dark red parenchyma without visible white pulp. There is an approximately 50 gram accessory spleen located near the hilum of the major spleen. There is an ill-defined amount of tan lobular unremarkable thymus tissue in the superior mediastinum. There is no lymph node enlargement.

Genitourinary System: The right kidney weighs 190 grams; the left kidney weighs 200 grams. Both have smooth subcapsular surfaces with well demarcated cortices and medullae. The parenchyma, in general, is pale. The pelves and vasculature are not remarkable. The ureters maintain uniform caliber into an unremarkable empty bladder. The ureters are intact and free of injury. The bladder shows focal mucosal hemorrhage consistent with catheterization. The prostate gland is appropriate for age. The testes are free of mass lesion.

Endocrine System: The pituitary gland is not enlarged. The thyroid gland is reddish-brown and without nodularity. The adrenal glands are unremarkable externally and upon sectioning.

Digestive System: The esophagus and gastroesophageal junction are unremarkable. The stomach contains approximately 5 ml. of viscous tan fluid without solid food or pills. The small intestine is remarkable for focal areas of dusky discoloration as well as the re-section of jejunum described above. There is hemorrhage at the base of the mesentery with surgical vascular ligatures present. The colon shows the previously noted changes and is otherwise unremarkable. The appendix is present in the right lower quadrant of the abdomen and unremarkable.

Musculoskeletal System: There are no fractures of the vertebrae, clavicles, ribs, or sternum. The pelvis shows the previously noted changes but is otherwise unremarkable. The musculature is normally distributed.

Toxicology: Specimens of blood, bile, gastric contents, vitreous humor and liver tissue are submitted for toxicological analysis as indicated. A separate report will be attached.

Radiology: Full body x-rays are made and retained.

Microscopy: Sections of heart, lung, liver, kidney, brain and pancreas are submitted for histopathologic analysis.

Microscopic Diagnosis:

HEART:	Unremarkable epicardium and coronary artery Myocardium without inflammation Endocardium unremarkable
LUNG:	Atelectasis with patchy edema No neutrophils
LIVER:	Moderate mononuclear cell infiltrate in portal areas Lobules with focal hepatocyte pallor near central veins
KIDNEY:	Glomeruli of normal size and cellularity Tubular autolysis Vessels unremarkable

Case: IN2014-01991
Name: Tamir E. Rice

County: Cuyahoga


BRAIN: Hippocampus section with slight vacuolization of white matter
No red neuron changes

PANCREAS: No histopathologic diagnosis
Autolysis present
No inflammation

OPINION: It is my opinion that Tamir E. Rice, a 12 year-old black adolescent male, died as a result of a gunshot wound to the abdomen which injured his inferior vena cava, intestines and pelvis. The decedent was shot by law enforcement during legal intervention.

CAUSE OF DEATH: Gunshot wound of torso with injuries of major vessel, intestines and pelvis.

MANNER OF DEATH: Homicide.



Thomas P. Gilson, M.D.
Medical Examiner

12/11/14

Date

JM

Dictated: 11/25/2014

Transcribed 11/26/2014